

**20  
20**

**20<sup>th</sup> Annual  
State of the Art  
WINTER  
Symposium**

**HONORING OUR HISTORY,  
FORGING OUR FUTURE**

**January 9–12, 2020 | Loews Miami Beach Hotel**

**To learn more or register, visit  
[ASTS.org/winter-symposium](https://ASTS.org/winter-symposium)**



**American Society of Transplant Surgeons®**

## LETTER TO THE EDITOR

# Histological picture of ABMR without HLA-DSA: Temporal dynamics of effector mechanisms are relevant in disease reclassification

To the Editor:

We read with great interest the letter by Bestard and Grinyo,<sup>1</sup> where they confirm our recent finding<sup>2</sup> that donor-specific human leukocyte antigen antibodies (HLA-DSA) are not present in an important fraction of cases with the histological picture of antibody-mediated rejection (ABMR<sub>h</sub>).

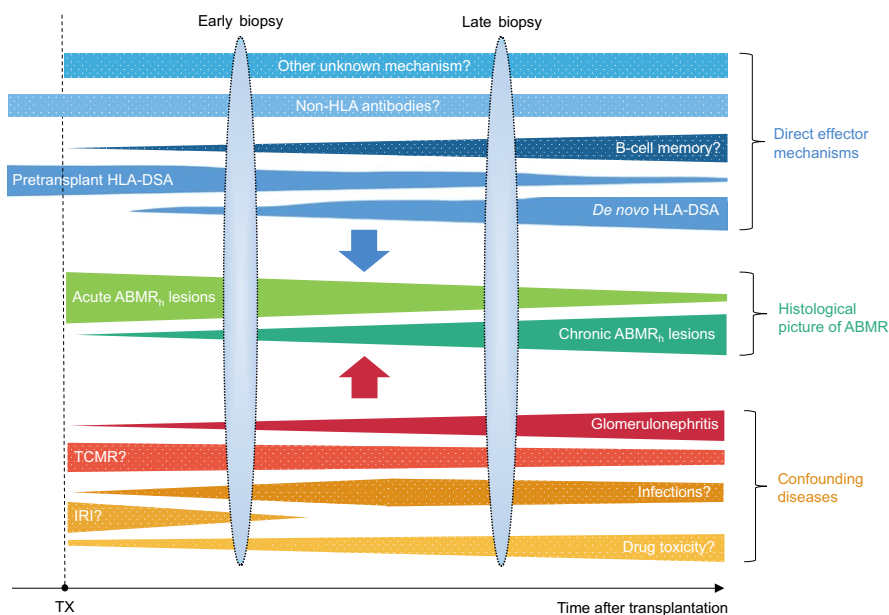
The large proportion of cases with ABMR<sub>h</sub> without HLA-DSA necessitates searching for novel markers for antibody involvement in the diagnosis of ABMR following kidney transplantation, or for other (antibody-independent) effector mechanisms contributing to this same histological picture like glomerulonephritis, drugs, infections, auto-immunity, and ischemia-reperfusion injury (Figure 1).

Recently, Luque et al<sup>3</sup> developed an HLA B cell ELISpot assay as a predictive and diagnostic tool for ABMR. High donor-reactive memory B cells (mBC) were demonstrated in all cases of DSA-positive acute ABMR cases, and in the majority of DSA-positive chronic ABMR cases. Interestingly, also 21 of 29 DSA-negative cases with (chronic) ABMR had circulating donor-reactive mBC, suggesting that a proportion of the patients with (chronic) ABMR<sub>h</sub> without HLA-DSA could be explained by B cell memory (and thus potentially missed prior HLA-DSA). In their new update, and building on our recent study,<sup>2</sup> Bestard and Grinyo now present that the majority (72%) of cases with DSA<sub>neg</sub>ABMR<sub>h</sub> (now also including the cases with acute lesions), also had donor-reactive mBC.<sup>1</sup> This new

analysis further supports the conclusion of their previous paper, that assessing the donor-reactive mBC may become a more sensitive marker for involvement of donor-specific allo-immunity than circulating HLA-DSA.

Although Bestard and Grinyo confirmed that DSA<sub>neg</sub>ABMR<sub>h</sub> is frequent,<sup>1</sup> their new analysis did not fully validate our finding that DSA<sub>neg</sub>ABMR<sub>h</sub> has better prognosis than DSA<sub>pos</sub>ABMR<sub>h</sub>. In their study, only the minority of cases where no mBC were found had better outcome. The association of DSA<sub>neg</sub>ABMR<sub>h</sub> with impaired graft outcome appeared to be driven by donor-specific mBC.

This discrepancy between our study<sup>2</sup> and the analysis presented by Bestard and Grinyo et al<sup>1</sup> illustrate that we should be very cautious in the details. The two studies had a very different study design. In our study, we used a "historical" definition of HLA-DSA negativity. Patients in whom DSA had been detected prior (mainly pretransplant, 84%) were allocated to DSA-positive group. In contrast, although not mentioned explicitly in their previous manuscript, Luque et al appear to utilize a "contemporary" definition, classifying patients based on their current DSA status, which mainly (91%) occurred de novo after transplantation.<sup>3</sup> We hypothesize that mBC may indeed be detectable in the circulation of patients with "resolved pretransplant DSA" or therapeutically removed de novo DSA. This patient group would be included in the DSA<sub>pos</sub>ABMR<sub>h</sub> arm of our study, but in the DSA<sub>neg</sub>mBC<sub>pos</sub>ABMR<sub>h</sub> arm of Bestard and



**FIGURE 1** Conceptual presentation of time-varying prevalence of pathophysiological and histological features of the histological picture of ABMR after kidney transplantation. Slopes and magnitudes do not represent actual data, but reflect general trends reported in the literature. Dotted fill colors and question marks indicate areas of major uncertainty. ABMR<sub>h</sub>, histological picture of ABMR; IRI, ischemia reperfusion injury; HLA-DSA, donor-specific HLA antibodies; TCMR, T-cell mediated rejection; TX, transplantation

Grinyo, which would thus explain inferior survival in the latter group, compared to the DSA<sub>neg</sub>mBC<sub>neg</sub>ABMR<sub>h</sub> arm. From this, it seems relevant to investigate to what extent cases of “resolved DSA” display positivity for donor-specific mBC and whether memory B cell monitoring surpasses “historical DSA positivity” as a diagnostic and predictive tool for ABMR.

In addition, the differences in study design also translated into differences in phenotypic presentation of the ABMR<sub>h</sub> cases. In our cohort study, 95% of patients fulfilled the histological criteria for active ABMR (only 5% had cg score > 0),<sup>2</sup> while in the partly cross-sectional study of Luque et al,<sup>3</sup> of the DSA<sub>neg</sub>ABMR<sub>h</sub> cases met the histological criteria for chronic active ABMR. The majority of ABMR<sub>h</sub> cases in the Barcelona study were diagnosed in (late) indication biopsies, with a mean biopsy time of 62 months after transplantation, which complicates the interpretation of their comparison with control biopsies obtained within the first 24 months after transplantation. Our survival analyses were based on diagnosis of DSA<sub>neg</sub>ABMR<sub>h</sub> identified within the first year after transplantation, which restricts our conclusions to the early period after transplantation, at which time the effector mechanisms or confounding diseases leading to ABMR<sub>h</sub> may be different, and which may translate into different impact on graft survival (Figure 1).

In conclusion, the discrepancies between our study and the data by Bestard and Grinyo illustrate that ABMR<sub>h</sub> likely reflects different underlying disease processes, with different kinetics over time and different association with outcome, as is also the case for the other kidney allograft pathologies.<sup>4</sup> Future clinical and translational studies should take this important heterogeneity and these time dependencies into account.

## DISCLOSURE

The authors of this manuscript have no conflicts of interest to disclose as described by the *American Journal of Transplantation*.

## ORCID

Aleksandar Senev  <https://orcid.org/0000-0002-6196-4669>

Jasper Callemeyn  <https://orcid.org/0000-0003-2235-9842>


Evelyne Lerut  <https://orcid.org/0000-0003-3937-7190>

Marie-Paule Emonds  <https://orcid.org/0000-0002-2653-8656>

Maarten Naesens  <https://orcid.org/0000-0002-5625-0792>

## Keywords

alloantibody, clinical research/practice, histocompatibility, immunobiology, kidney transplantation/nephrology, rejection: antibody-mediated (ABMR), translational research/science

Aleksandar Senev<sup>1,2,3</sup> 

Jasper Callemeyn<sup>1,2</sup> 

Evelyne Lerut<sup>4,5</sup> 

Marie-Paule Emonds<sup>1,3</sup> 

Maarten Naesens<sup>1,2</sup> 

<sup>1</sup>Department of Microbiology and Immunology, KU Leuven, Leuven, Belgium

<sup>2</sup>Department of Nephrology and Renal Transplantation, University Hospitals Leuven, Leuven, Belgium

<sup>3</sup>Histocompatibility and Immunogenetics Laboratory, Belgian Red Cross-Flanders, Mechelen, Belgium

<sup>4</sup>Department of Imaging and Pathology, KU Leuven, Leuven, Belgium

<sup>5</sup>Department of Pathology, University Hospitals Leuven, Leuven, Belgium

## Correspondence

Maarten Naesens

Email: [maarten.naesens@uzleuven.be](mailto:maarten.naesens@uzleuven.be)

## REFERENCES

- Bestard O, Grinyo J. Refinement of Humoral Rejection effector mechanisms to identify specific pathogenic histological lesions with different graft outcomes [published online ahead of print 2018]. *Am J Transplant*. <https://doi.org/10.1111/ajt.15171>.
- Senev A, Coemans M, Lerut E, et al. Histological picture of antibody-mediated rejection without donor-specific anti-HLA antibodies: Clinical presentation and implications for outcome [published online ahead of print 2018]. *Am J Transplant*. <https://doi.org/10.1111/ajt.15074>.
- Luque S, Lúcia M, Melilli E, et al. Value of monitoring circulating donor-reactive memory B cells to characterize antibody-mediated rejection after kidney transplantation [published online ahead of print 2018]. *Am J Transplant*. <https://doi.org/10.1111/ajt.15055>.
- Van Loon E, Lerut E, Naesens M. The time dependency of renal allograft histology. *Transpl Int*. 2017;30(11):1081-1091.